JOBNAME: jpo 24#6 2004 PAGE: 1 OUTPUT: Fri October 1 10:10:27 2004
lww/jpo/87469/6034

ORIGINAL ARTICLE

Effectiveness of Spinal Release and Halo-Femoral Traction in the Management of Severe Spinal Deformity

Charles T. Mehlman, DO, MPH, Mohammed J. Al-Sayyad, MD, FRCSC,† and Alvin H. Crawford, MD, FACS**

Abstract: The purpose of this retrospective review was to assess the effectiveness of spinal release and halo-femoral traction in the management of severe spinal deformity. Twenty-four patients had halo-femoral traction and a spinal release. Analysis focused on pre-traction curve, preoperative curve in bending or hyperextension films, final traction curve, traction weight as a percent of body weight, and complications associated with traction. The average pre-traction curve was 95 degrees and the average pre-traction curve in bending was 73 degrees; the final traction average curve was 44 degrees. The difference between the magnitude of curve correction in bending and traction films was statistically significant. Traction weight was increased to an average of 54% of body weight. The only complication was a bilateral lower extremity sensory deficit that resolved after traction weight reduction. The average final correction was 71%. Spinal release and halo-femoral traction offer a safe approach to the correction of severe spinal deformities before fusion.

Key Words: halo-femoral traction, spinal release, scoliosis

(*J Pediatr Orthop* 2004;24:667–673)

Perhaps the earliest reference to traction treatment of spinal deformity may be found in ancient Hindu texts, where Lord Krishna straightened the back of a female worshiper via traction applied chin to toe.[19] The literature includes a number of reports with good correction of severe spinal deformities using halo-femoral, halo-pelvic, and halo-gravity traction.[9–11,14,17,22,26,27,30,31,38] In 1959 Perry and Nickel introduced the halo device.[29] In 1967 Kane, Moe, and Lai described the use of halo-femoral traction.[18] Cotrel and others have shown prolonged soft tissue traction to be effective in correcting relatively inflexible curves.[4,5,9] In 1983 Lawhon and Crawford surveyed 145 Scoliosis Research Society members and other spine surgeons regarding traction treatment of spinal deformity and found that 79% believed that halo-femoral traction was indicated for severe and/or rigid curves; 85% defined this as curves exceeding 80 degrees.[20] Their survey indicated that other halo variants were also used to a lesser degree.

The major angular deformities of the spine seen in congenital scoliosis, neurofibromatosis, severe neuromuscular and idiopathic curves present challenges therapeutic to the spine surgeon. Perhaps the most feared complication of spinal deformity surgery is spinal cord injury and permanent paralysis. Patients with severely rigid or large curves are thought to be at increased risk of this complication. Halo-femoral traction has been suggested as a useful tool for gradual safe correction. The purpose of this study was to assess the safety and effectiveness of spinal release and halo-femoral traction in the management of severe spinal deformities.

MATERIALS AND METHODS

We conducted a retrospective database search for the period 1979 to 2000 aimed at identifying all spinal deformity patients whose treatment had included spinal release and halo-femoral traction. The data collected included patient age, gender, diagnosis, history of any previous treatment, type of anterior spinal release (open vs. thoracoscopic), duration of traction, weight used during traction, patient's weight, spinal surgeries after traction, type of bone graft used, and complications during traction treatment.

Deformities were measured on upright anteroposterior (AP) and lateral films using the Cobb method[3]; only the largest curve was included for analysis. Thoracic kyphosis was measured from T3 to T12. Films reviewed included pre-traction, best bending or hyperextension, final traction, and 1 year and final follow-up x-rays. The percentage correction was calculated initially, at 1 year, and at final follow-up. When calculating percentage correction for kyphosis cases, normal thoracic kyphosis was considered to be 40 degrees and the following equation was used: percentage of kyphosis correction = (100 × [preoperative kyphosis − (postoperative kyphosis − 40 degrees)])/preoperative kyphosis. If correction was to below 40 degrees, the correction was considered 100%.[2,25]

Surgical Technique

All the patients in the study had pre-traction anterior spinal release, posterior release, or a combination of the two. The operative procedure (as well as the postoperative traction care) is performed with the patient on a bed designed to accommodate traction pulleys and to allow for appropriate

Study conducted at Cincinnati Children's Hospital Medical Center, University of Cincinnati College of Medicine, Cincinnati, Ohio.
From the *Division of Pediatric Orthopaedics, Cincinnati Children's Hospital Medical Center, Cincinnati, Ohio; and †Department of Orthopedics, King Abdulaziz University Hospital, Jeddah, Saudi Arabia.
None of the authors received financial support for this research study.
Reprints: Charles T. Mehlman, DO, MPH, Division of Pediatric Orthopaedic Surgery, Cincinnati Children's Hospital Medical Center, 3333 Burnet Avenue, Building C, MLC #2017, Cincinnati, OH 45229-3039 (e-mail: ctmehlman@post.harvard.edu).
Copyright © 2004 by Lippincott Williams & Wilkins

supine and prone postioning (Stryker bed). Anterior release involves either open or video-assisted anterior release and discectomy. As annulus and disc space contents are excised, we strive to achieve an approximately 250-degree arc of release that extends from the near-side rib head to the far-side posterolateral body. Rib graft is then placed in the disc space to obtain fusion. Details about this technique have been published previously.[6,25] Posterior spinal release includes removal of facet capsular tissue and facetectomy at the anticipated levels of posterior spinal fusion. Following the spinal release, the halo-femoral traction is applied while the patient is under general anesthesia. The technique of halo application is best reviewed in Mubarak et al's article.[24] Threaded Steinmann pins are inserted into the distal part of the femur at least 2 cm proximal to the physis in the skeletally immature patient. Traction ropes are tied directly to the Steinmann pins and a wooden traction bar is used to equalize forces to both femurs and to allow the patient to be turned on the horizontal turning frame. Nutritional support is also offered via a Naso Duodenal feeding. The patient leaves the operating room with 5 pounds of traction applied to both ends of the frame.

Postoperative Care

Proper inpatient care includes detailed neurologic examination of the extremities and cranial nerves and assessment of bladder function. The addition of weights is routinely done during daylight hours when the patient is awake and alert and able to provide verbal feedback regarding neurologic-related questioning. Postoperatively a supine AP radiograph is obtained as a baseline assessment and every other day thereafter. Weight is immediately reduced if the patient develops any abnormal neurologic symptoms or signs. No additional weight is added if the patient's curve correction with traction has plateaued. Patients are taken to the operating room in traction and have their surgery on the Stryker bed with traction ropes clamped.

Statistical Analysis

Statistical analysis was done using SPSS for Windows version 9.0 (SPSS, Cary, NC). Continuous variables were analyzed using a two-tailed Student *t* test. Statistical results that achieved a *P* value of less than 0.05 were considered significant.

RESULTS

Twenty-four patients were treated in halo-femoral traction after spinal release and before their posterior fusion surgery. The average age of patients at the time of treatment was 14 (range 7–24) years. Patient data are provided in Table 1. Follow-up averaged 4.2 (range 2–7) years. Nineteen patients had an anterior release, four patients had anterior and posterior release, and one patient had only posterior release. Traction was used for an average of 9 (range 5–13) days before spinal fusion. When correction plateaued, all patients underwent posterior spinal fusion. Instrumentation and iliac crest bone grafting was used in all except two patients. Allograft was used in one patient with neuromuscular scoliosis and one patient with congenital scoliosis.

All patients had improvement in their deformity from the halo-femoral traction and spinal release. The average traction weight was 54% (range 20–113%) body weight. Initial curve measurement averaged 95 degrees (range 60–150 degrees). The best bending film curve measurement averaged 73 degrees (range 42–143 degrees). The correction obtained with bending averaged 29% (range 1–84%). At the end of traction treatment and thus immediately preceding fusion, the Cobb angle averaged 44 degrees (range 22–65 degrees) and the correction obtained averaged 59% (range 14–100%). The difference in curve magnitude between the best bend film and the final traction film was statistically significant ($P < 0.001$). After posterior spinal fusion and instrumentation, the Cobb angle averaged 32 degrees (range 10–60 degrees). Early correction obtained after the instrumented fusion averaged 71% (range 31–100%). The final correction after the instrumented fusion averaged 70% (range 26–100%). There was no statistically significant influence of age ($\leq$10 years vs. $>$10 years of age) on improvement in traction and final post-instrumented fusion x-rays ($P = 0.1$).

Complications occurred in three cases during traction care. One transient neurologic complication occurred in an 11-year-old boy with neurofibromatosis who had kyphoscoliosis measuring 145 degrees (the patient had undergone seven previous attempts to correct his spine and had mild neuropathy): after the anterior and posterior spine release and when the traction weight reached 69% of body weight, the patient developed bilateral lower extremity sensory deficit. This resolved totally when the traction was reduced to 61% of body weight. Neck pain occurred in a 10-year-old patient with Ehlers-Danlos syndrome at a weight of 47% body weight (9 kg); cervical spine x-rays showed distraction at discs from C3 to C7. The traction weight was reduced to 36.6% body weight (7 kg) and the neck pain resolved. Final follow-up x-rays failed to show any evidence of avascular necrosis of the odontoid process or arthritic changes. Iliac crest graft site infection occurred in a 15-year-old girl who had cerebral palsy with severe neuromuscular scoliosis; this was treated successfully with irrigation and debridement in addition to intravenous antibiotics. There were no cases of halo pin loosening, superficial pin site infections, cranial nerve irritation symptoms, deep vein thrombosis, hip stiffness, or instability in this series. Two case examples are provided in Figures1 and 2.

DISCUSSION

Spinal cord injury is the most feared complication of spinal deformity surgery, and patients with severely rigid or large curves are thought to be at increased risk of this complication.[7,15,32–34] Some have suggested that traction (without spinal release) offers no advantage over immediate spinal fusion with instrumentation.[8,35] Our study did not directly address this issue but focused instead on the effectiveness of spinal release and halo-femoral traction. The authors have accepted that halo-femoral traction after spine release provides safe, gradual correction in this selected patient population. The safety of this technique emanates from the fact that the correction is obtained in an awake patient whose neurologic status is closely monitored. We acknowledge

 © 2004 Lippincott Williams & Wilkins

JOBNAME: jpo 24#6 2004 PAGE: 3 OUTPUT: Fri October 1 10:10:32 2004
lww/jpo/87469/6034

TABLE 1. Patient Data

Case No.	Age (years)	Diagnosis	Time in Halo-femoral Traction (days)	Traction % of Body Weight	Traction Wt (kg)	Body Wt (kg)	Initial Cobb Angle	Best Bend Cobb Angle	% Curve Correction With Best Bend	Cobb Angle After Release and Traction	% Curve Correction With Release and Traction	Final Cobb Angle After Fusion	% Curve Final Correction
1	13.5	Idiopathic scoliosis	10	45%	22	49	92	72	22%	55	40%	57	38%
2	11	Neurofibromatosis	11	61%	14	23	145	143	1%	65	55%	52	64%
3	18	Osteogenesis imperfecta	7	66%	21	32	97	78	20%	46	53%	40	59%
4	10	Idiopathic scoliosis	7	43%	20	46	60	NA	NA	36	40%	10	83%
5	18	Idiopathic scoliosis	9	47%	31	66	99	74	25%	50	49%	60	39%
6	12	Idiopathic scoliosis	7	58%	21	36	77	42	45%	22	71%	10	87%
7	13	Idiopathic scoliosis	5	84%	36	43	93	90	3%	39	58%	36	61%
8	13	Idiopathic scoliosis	7	33%	36	110	76	68	11%	42	45%	18	76%
9	12	Congenital scoliosis	7	45%	13	29	80	48	40%	35	56%	29	64%
10	7	Congenital scoliosis	9	113%	17	15	62	58	12%	54	14%	25	60%
11	15	Scheuermann's kyphosis	13	33%	18	55	104	57	84%	40	100%	46	94%
12	14	Myelomeningocele, kyphoscoliosis	8	55%	18	33	145	91	37%	61	86%	19	87%
13	15	Neuromuscular scoliosis	8	53%	17.5	33	112	93	17%	53	53%	42	62%
14	7	Neuromuscular scoliosis	7	35%	NA	NA	136	75	45%	42	69%	58	57%
15	9	Myelomeningocele	5	68%	17	25	85	64	25%	35	59%	24	71%
16	12	Idiopathic scoliosis	8	71%	28	40	83	62	25%	31	63%	15	81%
17	10	Idiopathic scoliosis	11	56%	27	48	84	56	33%	32	62%	25	70%
18	12	Idiopathic scoliosis	5	50%	NA	NA	91	60	34%	34	63%	18	80%
19	14	Neurofibromatosis	7	44%	27	61	67	65	3%	40	42%	20	70%
20	24	Scheuermann's kyphosis	12	62%	31	50	95	58	39%	51	88%	41	98%
21	18	Idiopathic scoliosis	13	20%	13	65	89	70	21%	39	56%	54	39%
22	15	Idiopathic scoliosis	6	51%	18	35	90	80	11%	38	58%	14	84%
23	14	Post laminectomy kyphosis	12	43%	17	40	75	NA	NA	50	87%	22	100%
24	10	Ehlers-Danlos	10	47%	9	19	131	100	24%	63	52%	37	72%

that some authors might advocate acute correction via same-day "front and back" surgery on patients such as ours without an intervening period of traction. Whereas this is certainly possible, we do not believe it is possible to achieve a lower permanent neurologic complication rate (0%) in patients with severe spinal deformities such as those described in the present study.

As mentioned earlier, the use of traction to correct spinal deformity may date back as far as 3500 BC.[16] The use of traction of various types, including halo-pelvic, halo- gravity, and halo-femoral, has been well documented in the literature.[9,11,13,22,26,27,31,35,36,38,43] Few recent reports have discussed halo traction for rigid spinal deformity. Sink et al[31] used halo-gravity traction in 19 children; traction was used for 6 to 21 weeks, and not all their patients had spinal release. Some of their patients had the release after 6 weeks of traction. No information was provided regarding bending films or other measures of curve flexibility, but the curves were considered to

© 2004 Lippincott Williams & Wilkins

JOBNAME: jpo 24#6 2004 PAGE: 4 OUTPUT: Fri October 1 10:10:34 2004
lww/jpo/87469/6034

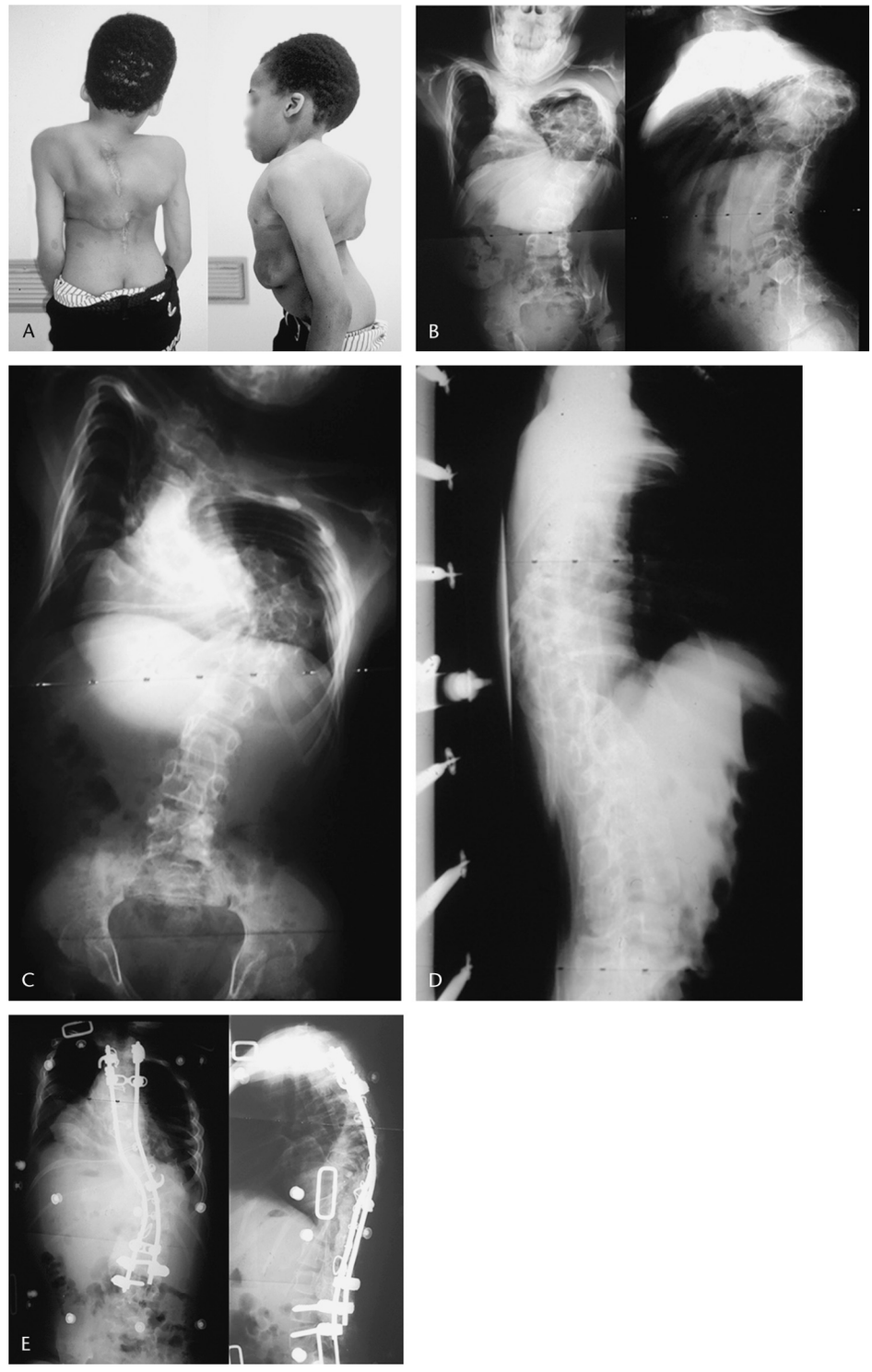

FIGURE 1. An 11-year-old boy with neurofibromatosis and rigid kyphoscoliosis. This patient had undergone seven prior spinal surgeries elsewhere before being treated by our traction protocol. A, Clinical photograph before treatment. B, AP and lateral radiographs before treatment showing right thoracic scoliosis measuring 145 degrees. C, AP best bend radiograph showing curve correction to 143 degrees. D, Lateral final radiograph before posterior spinal fusion. E, AP and lateral radiographs at 2-years follow-up showing solid spinal fusion with a 52 degree curve.

be rigid. The Cobb angle in that series improved 35% from an average 84 degrees before traction to 55 degrees preceding fusion. Arlet et al[1] reported on the use of halo-femoral traction to treat a 17-year-old girl with a multioperated congenital scoliosis of 145 degrees and cor pulmonale. The patient had posterior release and implantation of sliding rods connected to non-screw-tightened connectors (loose dominos), and correction was achieved over a 3-week period in halo-femoral traction. Correction of the deformity and improvement in pulmonary function were achieved.

In 1997 Flierl and Carstens[12] reported on the use of halo-gravity traction in 32 patients with neuromuscular

 © 2004 Lippincott Williams & Wilkins

JOBNAME: jpo 24#6 2004 PAGE: 5 OUTPUT: Fri October 1 10:10:49 2004
lww/jpo/87469/6034

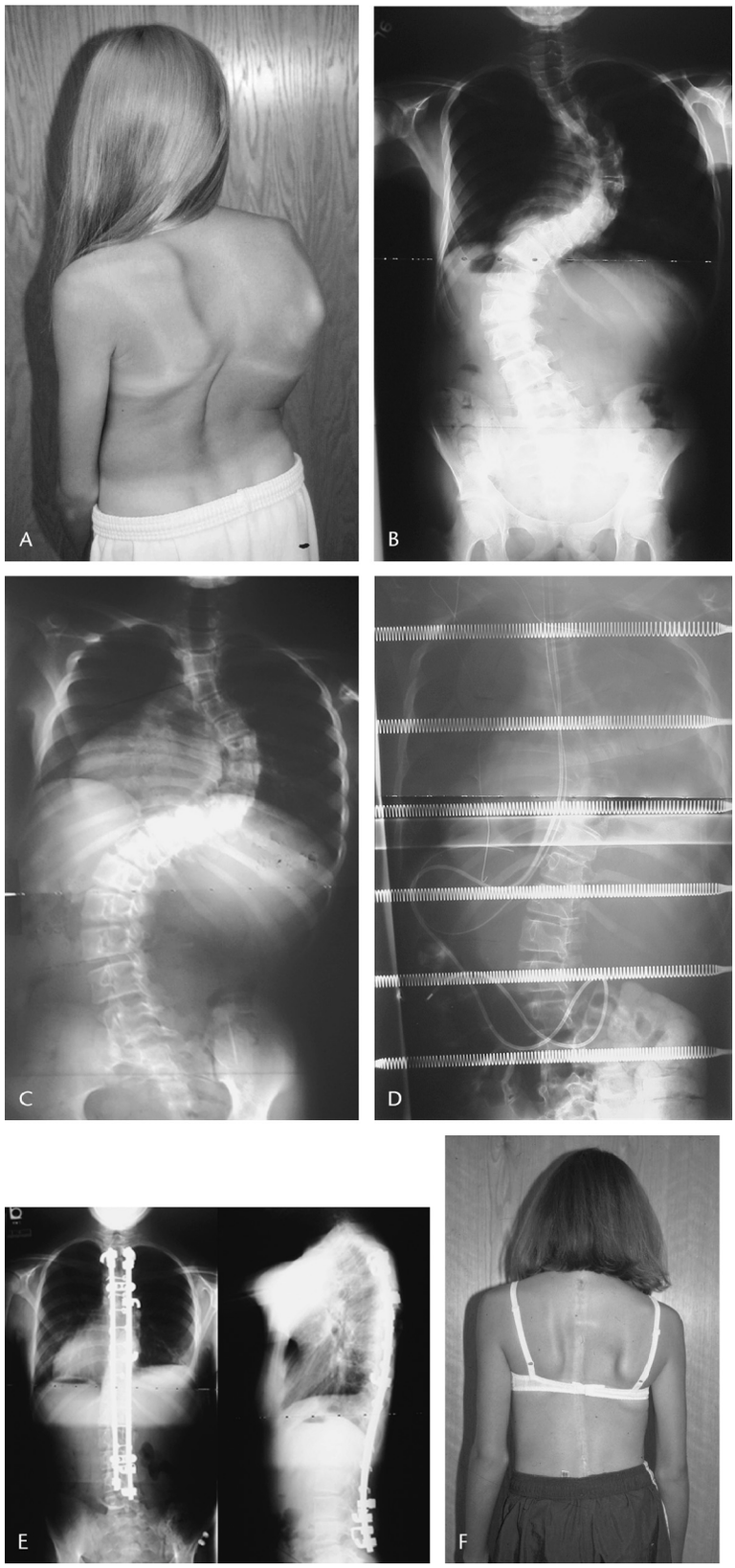

FIGURE 2. A 15-year-old girl with idiopathic scoliosis. A, Clinical photograph before treatment. B, AP radiographs before treatment showing thoracic scoliosis measuring 90 degrees. C, AP best bend radiograph showing curve correction to 80 degrees. D, AP final traction radiograph before posterior spinal fusion showing curve correction to 38 degrees. E, AP and lateral radiographs at 5-years follow-up showing solid spinal fusion with a 22-degree curve. F, Clinical photograph after treatment.

© 2004 Lippincott Williams & Wilkins

JOBNAME: jpo 24#6 2004 PAGE: 6 OUTPUT: Fri October 1 10:11:02 2004
lww/jpo/87469/6034

scoliosis; they believed the technique did not improve the ultimate outcome after fusion surgery and concluded that preoperative halo-gravity traction cannot be recommended in paralytic scoliosis. Huang and Lenke[16] reported on the use of intraoperative halo-femoral traction in a case of severe scoliosis and associated pelvic obliquity in a 14-year-old patient with cerebral palsy. The patient underwent an anterior spinal fusion from T10 to S1 and a posterior spinal fusion from T2 to the pelvis; the posterior procedure was performed with the patient in intraoperative halo-femoral traction. The patient responded well to the surgical intervention and had a stable correction of his pelvic obliquity. In 1994 Loniewski de Ninina and Dubousset[23] reviewed 20 adolescents who had rigid kyphosis or kyphoscoliosis; they used preoperative traction for a mean of 25 days and gained an improvement of 14% at the final correction. In our series, curve correction obtained after spine release and traction averaged 59% (range 14–100%), which is a significant improvement when compared with the correction obtained in best bend film, which averaged 29% (range 1–84%). This statistically significant difference documents the efficacy of this technique.

Previously reported complications with traction have included pin loosening and pin site infection in 5 of 22 cases reported by Sink et al[31]; brain abscess has also been previously described with halo pins.[40] No pin-related complications were encountered in our series. This may have been due to the relatively short period of traction treatment used in our patients. Avascular necrosis of the odontoid process and cervical spondylosis have been previously reported with spinal traction as a result of prolonged periods of distraction of the odontoid and apophyseal joints, respectively.[10,17,26,30,38,39] Cranial nerve complications were reported in 1 of 22 cases in Sink et al's series,[31] in a patient with Klippel-Feil syndrome who developed numbness of the roof of the mouth after 6 weeks of halo-gravity traction. Wilkins and MacEwen[42] reported that cranial nerve complications occurred in 6 of their 70 cases, with the abducens nerve being most affected; on release of traction, the neurologic deficit disappeared. We did not encounter any cranial nerve deficits in this series.

Spinal cord complications remain the most worrisome issue associated with the treatment of patients with severe spinal deformity. Wilkins and MacEwen[42] noted particular susceptibility of myelomeningocele and post-radiation spinal deformity patients to halo traction-associated paresis. Our only temporary neurologic event was a bilateral lower extremity sensory deficit in a child with neurofibromatosis, and it resolved completely when traction weight was reduced to 61% of body weight (14 kg). Leslie et al,[21] in a study of 54 patients who had halo-femoral traction, reported the incidence of deep vein thrombosis to be 3.7% (two patients), and clinically silent thrombosis did not occur. Perry[28] reported hip dislocation and other hip abnormalities with halo-femoral traction. Monitoring techniques and surgical techniques have both evolved over the years, and this makes the older literature difficult to compare directly with more recent studies.

Biomechanical data exist that assert that longitudinal forces offer greater corrective force than transverse forces in the setting of curves greater than about 55 degrees.[41] If this is the case, it is possible that our bending radiographs may have underestimated the flexibility of the very large curves included in the present study. A clinical study by Takahashi et al[37] found that traction radiography and supine side-bending radiography (such as that used in our study) were "practically equivalent in terms of evaluating the reducibility of curves." These clinical data would tend to refute the biomechanical concerns over bending films.

When compared with previous publications that did not include spinal release as a routine in all the patients,[21,31,38] our patients had shorter periods of traction (average of 9 days), which may explain why we did not encounter significant traction-related complications. Close monitoring of the neurologic status of these patients cannot be overemphasized. Our results show that halo-femoral traction is a safe and effective adjunct in the treatment of the challenging patients with severely rigid or large curves. The spinal release and halo-femoral traction protocol outlined offer a safe, controlled approach to the reduction of severe spine deformities before fusion.

ACKNOWLEDGMENT

The authors thank Donald M Sandercock II, DO, for research assistance.

REFERENCES

1. Arlet V, Papin P, Marchesi D. Halo femoral traction and sliding rods in the treatment of a neurologically compromised congenital scoliosis: technique. *Eur Spine J*. 1999;8:329–331.
2. Bernhardt M, Bridwell KH. Segmental analysis of the sagittal plane alignment of the normal thoracic and lumbar spines and thoracolumbar junction. *Spine*. 1989;14:717–721.
3. Cobb J. Outline for the study of scoliosis. *AAOS Instr Course Lect*. 1948;5:261–275.
4. Cotel Y. A new technique of correction and fusion. *Isr J Med Sci*. 1973;9:759–766.
5. Cotel Y. Traction in the treatment of vertebral deformity. *J Bone Joint Surg [Br]*. 1975;57:260.
6. Crawford AH, Wall EJ, Wolf R. Video-assisted thoracoscopy. *Orthop Clin North Am*. 1999;30:367–385.
7. Cummine JL, Lonstein JE, Moe JH, et al. Reconstructive surgery in the adult for failed scoliosis fusion. *J Bone Joint Surg [Am]*. 1979;61:1151–1161.
8. Curtis RS, Dickson JH, Harrington PR, et al. Results of Harrington instrumentation in the treatment for severe scoliosis. *Clin Orthop*. 1979; 128–134.
9. Dewald RL, Ray RD. Skeletal traction for the treatment of severe scoliosis. The University of Illinois halo-hoop apparatus. *J Bone Joint Surg [Am]*. 1970;52:233–238.
10. Dove J, Hsu LC, Yau AC. The cervical spine after halo-pelvic traction. An analysis of the complications of 83 patients. *J Bone Joint Surg [Br]*. 1980;62:158–161.
11. Edgar MA, Chapman RH, Glasgow MM. Pre-operative correction in adolescent idiopathic scoliosis. *J Bone Joint Surg [Br]*. 1982;64:530–535.
12. Flierl S, Carstens C. The effect of halo-gravity traction in the preoperative treatment of neuromuscular scoliosis. *Z Orthop Ihre Grenzgeb*. 1997; 135:162–170.
13. Floman Y, Penny JN, Micheli LJ, et al. Osteotomy of the fusion mass in scoliosis. *J Bone Joint Surg [Am]*. 1982;64:1307–1316.
14. Ginsburg GM, Bassett GS. Hypoglossal nerve injury caused by halo-suspension traction. A case report. *Spine*. 1998;23:1490–1493.
15. Gui L, Savini R, Vicenzi G, et al. Surgical treatment of poliomyelitic scoliosis. *Ital J Orthop Traumatol*. 1976;2:191–205.
16. Huang MJ, Lenke LG. Scoliosis and severe pelvic obliquity in a patient with cerebral palsy: surgical treatment utilizing halo-femoral traction. *Spine*. 2001;26:2168–2170.
17. Kalamchi A, Yau AC, O'Brien JP, et al. Halo-pelvic distraction apparatus. An analysis of one hundred and fifty consecutive patients. *J Bone Joint Surg [Am]*. 1976;58:1119–1125.

 © 2004 Lippincott Williams & Wilkins

JOBNAME: jpo 24#6 2004 PAGE: 7 OUTPUT: Fri October 1 10:11:03 2004
lww/jpo/87469/6034

18. Kane W, Moe J, Lai C. Halo-femoral pin distraction in the treatment of scoliosis. *J Bone Joint Surg [Am]*. 1967;49:1018–1019.
19. Kumar K. Spinal deformity and axial traction. *Spine*. 1996;21:653–655.
20. Lawhon S, Crawford A. Traction in the treatment of spinal deformity. *Orthopaedics*. 1983;4:447–451.
21. Leslie IJ, Dorgan JC, Bentley G, et al. A prospective study of deep vein thrombosis of the leg in children on halo-femoral traction. *J Bone Joint Surg [Br]*. 1981;63:168–170.
22. Letts RM, Palakar G, Bobecko WP. Preoperative skeletal traction in scoliosis. *J Bone Joint Surg [Am]*. 1975;57:616–619.
23. Loniewski de Ninina X, Dubousset JF. The place of traction and the anterior approach in the surgical treatment of kyphosis and kyphoscoliosis in children using C.D. instrumentation. *Int Orthop*. 1994;18:195–203.
24. Mubarak SJ, Camp JF, Vuletich W, et al. Halo application in the infant. *J Pediatr Orthop*. 1989;9:612–614.
25. Newton PO, Shea KG, Granlund KF. Defining the pediatric spinal thoracoscopy learning curve: sixty-five consecutive cases. *Spine*. 2000; 25:1028–1035.
26. O'Brien JP, Yau AC, Hodgson AR. Halo pelvic traction: a technique for severe spinal deformities. *Clin Orthop*. 1973;93:179–190.
27. O'Brien JP, Yau AC, Smith TK, et al. Halo pelvic traction. A preliminary report on a method of external skeletal fixation for correcting deformities and maintaining fixation of the spine. *J Bone Joint Surg [Br]*. 1971; 53:217–229.
28. Perry J. The halo in spinal abnormalities: practical factors and avoidance of complications. *Orthop Clin North Am*. 1972;3:69–80.
29. Perry J, Nickel V. Total-cervical spine fusion for neck paralysis. *J Bone Joint Surg [Am]*. 1959;41:37–60.
30. Ransford AO, Manning CW. Complications of halo-pelvic distraction for scoliosis. *J Bone Joint Surg [Br]*. 1975;57:131–137.
31. Sink EL, Karol LA, Sanders J, et al. Efficacy of perioperative halo-gravity traction in the treatment of severe scoliosis in children. *J Pediatr Orthop*. 2001;21:519–524.
32. Stagnara P. Utilization of Harrington's device in the treatment of adult kyphoscoliosis above 100 degrees. Paper presented at: Fourth International Symposium on the Operative Treatment of Scoliosis, 1971.
33. Stagnara P, Fleury D, Fauchet R, et al. Major scoliosis over 100 degrees in adults: 183 surgically treated cases. *Rev Chirurgie Orthop*. 1975;61: 101–122.
34. Stagnara P, Jouvinrous P, Peloux R, et al. Cypho scolioses essentielles de l'adult foimes severes de plus de 100 degrees. Paper presented at: Redressement Partial et Arthrodeses. XI SICOT Congress, 1969; Mexico City, Mexico.
35. Swank S, Lonstein JE, Moe JH, et al. Surgical treatment of adult scoliosis. A review of two hundred and twenty-two cases. *J Bone Joint Surg [Am]*. 1981;63:268–287.
36. Swank SM, Winter RB, Moe JH. Scoliosis and cor pulmonale. *Spine*. 1982;7:343–354.
37. Takahashi S, Passuti N, Delecrin J. Interpretation and utility of traction radiography in scoliosis surgery. Analysis of patients treated with Cotrel-Dubousset instrumentation. *Spine*. 1997;22:2542–2546.
38. Tredwell SJ, O'Brien JP. Apophyseal joint degeneration in the cervical spine following halo-pelvic distraction. *Spine*. 1980;5:497–501.
39. Tredwell SJ, O'Brien JP. Avascular necrosis of the proximal end of the dens. A complication of halo-pelvic distraction. *J Bone Joint Surg [Am]*. 1975;57:332–336.
40. Victor DI, Bresnan MJ, Keller RB. Brain abscess complicating the use of halo traction. *J Bone Joint Surg [Am]*. 1973;55:635–639.
41. White A, Panjabi M. *Clinical Biomechanics of the Spine*. Philadelphia: JB Lippincott, 1990.
42. Wilkins C, MacEwen GD. Cranial nerve injury from halo traction. *Clin Orthop*. 1977:106–110.
43. Winter RB, Moe JH, Lonstein JE. Posterior spinal arthrodesis for congenital scoliosis. An analysis of the cases of two hundred and ninety patients, five to nineteen years old. *J Bone Joint Surg [Am]*. 1984; 66:1188–1197.

© *2004 Lippincott Williams & Wilkins*